

# Clinical outcomes of thyroid tumours with concurrent epithelial and mesenchymal components in 14 dogs (2006–2020)

Matthew R. Cook<sup>1</sup>  | Molly Gasparini<sup>1</sup> | Rachel E. Cianciolo<sup>2</sup> | Megan E. Brown<sup>1</sup> |  
 Antony S. Moore<sup>3</sup>  | Kaitlin M. Curran<sup>4</sup>  | Elizabeth A. Maxwell<sup>5</sup>  |  
 Shelby Gasson<sup>6</sup> | Brandan G. Wustefeld-Janssens<sup>6,7</sup> | Sridhar M. Veluvolu<sup>8</sup> |  
 Samuel Keepman<sup>9</sup> | Raelene Wouda<sup>10</sup> | Lynn R. Griffin<sup>7</sup> | Laura E. Selmic<sup>1</sup> 

<sup>1</sup> Department of Veterinary Clinical Sciences, College of Veterinary Medicine at The Ohio State University, Columbus, Ohio, USA

<sup>2</sup> Department of Veterinary Biosciences, College of Veterinary Medicine at The Ohio State University, Columbus, Ohio, USA

<sup>3</sup> Veterinary Oncology Consultants, Lake Innes, New South Wales, Australia

<sup>4</sup> Department of Clinical Sciences, Carlson College of Veterinary Medicine, Oregon State University, Corvallis, Oregon, USA

<sup>5</sup> Department of Small Animal Clinical Sciences, University of Florida College of Veterinary Medicine, Gainesville, Florida, USA

<sup>6</sup> Department of Small Animal Clinical Sciences, College of Veterinary Medicine and Biomedical Sciences, Texas A&M University, College Station, Texas, USA

<sup>7</sup> Department of Environmental and Biologic Health Sciences, Colorado State University, Fort Collins, Colorado, USA

<sup>8</sup> William R. Pritchard Veterinary Medical Teaching Hospital, School of Veterinary Medicine, University of California, Davis, Davis, California, USA

<sup>9</sup> Department of Clinical Sciences, School of Veterinary Medicine, University of Wisconsin, Madison, Wisconsin, USA

<sup>10</sup> Department of Clinical Sciences, College of Veterinary Medicine, Kansas State University, Manhattan, Kansas, USA

## Correspondence

Laura E. Selmic, BVetMed (Hons), MPH,  
 DACVS-SA, DECVS, Department of Veterinary  
 Clinical Sciences, The Ohio State University  
 College of Veterinary Medicine, 601 Vernon L.  
 Sharp St, Columbus, OH 43210, USA.  
 Email: [selmic.1@osu.edu](mailto:selmic.1@osu.edu)

## Funding information

National Cancer Institute, Bethesda, MD,  
 Grant/Award Number: P30 CA16058

## Abstract

**Background:** While rare, multiple individual case reports have described mixed thyroid tumours in dogs containing both epithelial and mesenchymal neoplastic components.

**Objectives:** In this retrospective case series, we describe the clinical presentation, treatment and outcome of 14 dogs of canine thyroid tumours with concurrent mesenchymal and epithelial neoplastic populations.

**Methods:** Fourteen cases were retrospectively abstracted from nine institutions. Histopathologic samples and reports were collected from 10/14 dogs and reviewed by a single board-certified anatomic pathologist.

**Results:** All 14 dogs had curative-intent surgery to remove the thyroid neoplasm. The most common surgery performed was a unilateral thyroidectomy (10/14 dogs). Post-operatively, systemic therapy was administered in eight dogs. Six dogs developed local recurrence with a median time to loco-regional recurrence of 53 days. Ten dogs developed metastatic disease with the most common metastatic site being the lungs (6/10 dogs), with a median time to metastasis of 93 days. Ten dogs were euthanised due to locoregional or distant progression of their mixed thyroid neoplasm. The overall

This is an open access article under the terms of the [Creative Commons Attribution-NonCommercial-NoDerivs](https://creativecommons.org/licenses/by-nc-nd/4.0/) License, which permits use and distribution in any medium, provided the original work is properly cited, the use is non-commercial and no modifications or adaptations are made.

© 2022 The Authors. *Veterinary Medicine and Science* published by John Wiley & Sons Ltd.

median survival time was 156 days (95%CI: 49–244). The median survival time for dogs treated with adjuvant therapy was 189 days (95%CI: 24–244), whereas dogs without adjuvant therapy had a median survival time of 156 days (95%CI: 35–upper limit could not be calculated;  $p = 0.62$ ).

**Conclusion:** The thyroid tumours with both mesenchymal and epithelial components in this small sample set were associated with a poor prognosis after surgical excision with or without adjunctive therapy.

#### KEYWORDS

canine, carcinoma, sarcoma, thyroid, tumour

## 1 | INTRODUCTION

Thyroid neoplasia accounts for 1.1–3.8% of all canine tumours (Barber, 2007). Thyroid tumours may arise from either epithelial or mesenchymal origins. Thyroid tumours can also be biologically benign or malignant (von Sandersleben & Hänichen, 1974). Malignant epithelial thyroid tumours have been histopathologically described as follicular, medullary, squamous or anaplastic carcinomas, whereas malignant mesenchymal tumours that have been described in the thyroid include fibrosarcoma, osteosarcoma, chondrosarcoma and other sarcomas (von Sandersleben & Hänichen, 1974). Additionally, coexistent and malignant mixed tumours, such as carcinosarcomas, have been described (von Sandersleben & Hänichen, 1974).

Carcinosarcomas are a distinct neoplasm in which both malignant epithelial and mesenchymal cells are present on histopathology. In contrast to carcinosarcomas where both components of the tumour are neoplastic, mixed tumours are tumours with distinct concurrent epithelial and mesenchymal neoplastic populations of cells are present, though each individual component can be benign or malignant. Carcinosarcomas are rare in the dog and have been described in the thyroid gland (Buergelt, 1968; Fernandez et al., 2008; Giuliano et al., 2013; Grubor & Haynes, 2005; Johnson & Patterson, 1981; Mason & Wells, 1929; Wells, 1901, ), mammary gland (Benjamin et al., 1999; Rasotto et al., 2017; Canadas et al., 2019), lung (Salas et al., 2002), eyelid (Hirai et al., 1997), salivary gland (Lieske & Rissi, 2020; Pérez-Martínez et al., 2000) and ceruminous gland (Moisan & Watson, 1996).

Only a few case reports exist describing the diagnosis, treatment and clinical outcomes for dogs with thyroid carcinosarcoma and mixed thyroid tumours (Grubor & Haynes, 2005; Buergelt, 1968; Mason & Wells, 1929; Wells, 1901; Giuliano et al., 2013; Fernandez et al., 2008; Johnson & Patterson, 1981). These reports suggest that preoperative cytological diagnosis is difficult, typically due to the heterogeneous biology of this neoplasm. Moreover, histopathologic diagnosis is challenging as these tumours are heterogeneous, requiring careful evaluation of multiple tissue sections to visualise the contrasting neoplastic populations. Often, a definitive diagnosis is only achieved following careful histologic evaluation of multiple regions of the tumour and immunohistochemical staining. Even then, histopathological reports

can be inconsistent in their description of this unusual neoplasm, as epithelial to mesenchymal transition (EMT) or osseous or fibrous metaplasia can occur, making clinical interpretation difficult.

Knowledge of the clinical presentation, diagnostic findings and outcomes for dogs with malignant mixed thyroid tumours is limited due to its rarity. Case reports detailing mixed thyroid tumours in dogs do not describe treatment or post-treatment outcomes as the diagnosis is often made post-mortem (Fernandez et al., 2008; Johnson & Patterson, 1981). The reported treatment approaches for these tumours vary, though they have included local control with surgical excision or radiotherapy with or without adjuvant systemic therapy (Grubor & Haynes, 2005; Giuliano et al., 2013). However, despite aggressive treatment, reported survival times are between 2 days (Fernandez et al., 2008) and 7 months (Johnson & Patterson, 1981).

The purpose of this retrospective case series was to describe the clinical behaviour, features, diagnosis, treatment and outcomes in a larger cohort of dogs diagnosed with malignant mixed thyroid tumours, specifically evaluating measures of outcomes following primary surgical excision, with or without adjunctive systemic therapy.

## 2 | MATERIALS AND METHODS

### 2.1 | Patient selection

A multi-institutional retrospective case series was conducted. Cases were solicited via the American College of Veterinary Internal Medicine (ACVIM) Oncology Listserve. Collaborators from academic and private veterinary practices searched their respective institutional electronic medical record systems for client-owned dogs that were diagnosed with thyroid carcinosarcoma. Dogs were eligible for inclusion in the study if they had a diagnosis of a carcinosarcoma or malignant mixed thyroid tumour confirmed via histopathology and had surgical excision of their primary thyroid tumour. Exclusion criteria included dogs that did not have a histopathological diagnosis of a mixed (epithelial and mesenchymal) tumour, no available histopathologic report for review, or dogs that did not undergo any form of treatment.

## 2.2 | Medical record review

Medical records were reviewed at each institution and the information collected included the date of birth, sex, neuter status, breed and body weight at the time of thyroid tumour diagnosis. Data were collected regarding the history and physical examination at the time of presentation, clinical signs at the time of presentation, duration of clinical signs, size of thyroid mass and affected side of thyroid tumour (left versus right). Information was abstracted regarding whether preoperative diagnostic tests were performed and if abnormal findings were present. Baseline thyroid hormone levels were collected when available.

Any treatment for the mixed thyroid neoplasm including surgery, radiation therapy or chemotherapy, and dates of treatment were recorded. Information was collected about surgical procedure performed, presence of metastasis at surgery, and whether perioperative complications occurred. For dogs that received adjuvant systemic therapy, the drug, dosage and adverse events were recorded. End points evaluated were dates of locoregional recurrence, metastasis development and death or euthanasia. Cytologic or histopathologic confirmation of locoregional recurrence or metastatic disease was requested and utilised, when available. For dogs that were still alive at the time of data collection, the date of last contact was recorded. If data regarding outcomes were missing from the medical record, the dog owner or primary veterinarian were contacted to gather additional information.

## 2.3 | Histopathologic review

Unstained slides from available histopathologic samples were submitted for review by a single board-certified anatomic pathologist (RC). Unstained slides were stained with haematoxylin and eosin (H & E) and the immunohistochemical markers vimentin, cytokeratin and thyroid transcription factor 1 (TTF-1). Samples were examined to assess for the presence of malignant mesenchymal and epithelial components, percentage of cells staining positively for the three IHC markers, as subjectively assessed by a board-certified pathologist, presence or absence of local and vascular invasion and presence or absence of necrosis. In four dogs where tumour samples were not available to be sent for pathologic review, histopathology reports were evaluated.

## 2.4 | Statistical analysis

Categorical variables were described with frequencies and percentages. Continuous variables were tested for normality using skewness, kurtosis and Shapiro Wilk tests. If variables were normally distributed, the mean and standard deviation (SD) were used for description. If the variables were non-normally distributed, the median and interquartile range (IQR) were used for description. Kaplan–Meier analysis was used to generate survival curves for time to metastasis (TTM), time to locoregional recurrence (TTLR) and overall survival time (OST). Median TTM, TTLR and OST with 95% confidence intervals (95% CI) were cal-

culated. TTM was defined as the interval between the date of surgery and the time of detection of metastatic disease. TTLR was defined as the interval between surgery and the time to the detection of recurrence of locoregional disease. OST was defined as the interval between the date of surgery and date of death/euthanasia or date of last follow-up. Dogs without metastatic disease, without locoregional recurrence or alive or lost to follow-up, were censored at the date of last contact.

## 3 | RESULTS

Fifteen dogs were identified and abstracted by contributing authors from eight academic institutions and one private practice, between the years of 2006 and 2020. One dog was excluded from analysis as histopathology was not performed. Fourteen dogs were included in the analysis, three from Veterinary Oncology Consultants, two from the Ohio State University, two from Oregon State University, two from the University of Florida and one from each of the following institutions; the University of California at Davis, Texas A&M University, Kansas State University, University of Wisconsin, and Colorado State University. The median age at diagnosis was 10.5 years (range 6–15 years, IQR 3). The median body weight at the time of diagnosis was 27.9 kg (range 13–45.5 kg, IQR 10.1). There were 10 castrated males and four spayed female dogs. The most common breed represented was the Labrador retriever breed ( $n = 5$ ). Demographic characteristics of each dog is summarised in Table 1.

The most common presenting complaints were a cervical mass in 9/14 of the dogs and a cough in 6/14 dogs. One dog had a cervical mass noted as an incidental finding during staging for a frontal sinus squamous cell carcinoma. The median duration of clinical signs before presentation was 21 days (range 3–1460 days).

Thirteen out of 14 dogs had haematology performed at presentation. Clinically relevant abnormalities included a mature neutrophilia ( $>10.8$  k/ $\mu$ L) in four dogs and thrombocytosis ( $> 463$  k/ $\mu$ L) in three dogs. One dog presented with an elevated haematocrit ( $>59\%$ ; 60.6%, dog 10) with normal renal parameters on serum biochemistry. All 14 dogs had serum biochemistry performed at presentation. Clinically relevant abnormalities included total calcium elevations in two dogs (13.6 g/dL dog 6 and 14.6 g/dL dog 8), mildly elevated alkaline phosphatase elevations in 4 dogs ( $>133$  IU/L; 249 IU/L dog 1, 338 IU/L dog 7, 313 IU/L dog 9 and 470 IU/L dog 13), mild blood urea nitrogen elevations in two dogs ( $> 27$  mg/dL; 32 mg/dL dog 1 and 44 mg/dL dog 12) and an elevated creatinine in one dog ( $>1.3$  mg/dL; 2.0 mg/dL dog 12). In seven dogs, a total T4 level was reported at presentation. One dog was reported to have an elevated total T4 at baseline, though the specific total T4 value was not available.

Twelve of 14 dogs had baseline thoracic imaging with 10 dogs having thoracic radiographs and four dogs having thoracic computed tomography (CT). In 3 of the 12 patients (dogs 2, 6 and 13), pulmonary nodules were detected and suspected to represent pulmonary metastatic disease. In one dog (dog 6), no evidence of pulmonary nodules was observed on thoracic radiographs; however, on CT, multiple pulmonary nodules were identified. This dog also had radiographic changes

**TABLE 1** Demographic and initial presentation information about 14 canine malignant mixed thyroid tumours

Dog Number	Age (years)	Sex	Breed	Weight (kg)	Presenting complaint	Longest measurement (cm)	Pre-op cytology (C) or incisional biopsy (B)
1	15	FS	Siberian Husky	13	Cervical mass, coughing, weight loss, dysphonia, pitting facial oedema	12	Mesenchymal neoplastic population and neuroendocrine population (C)
2	9	MC	Siberian Husky	45.5	Cervical mass	9	Grade III soft tissue sarcoma (B)
3	10	MC	Golden Retriever	34	Lethargy, hyporexia	6	Markedly septic with mixed inflammation (C)
4	9	MC	Golden Retriever	29.9	Cervical mass	8	Neuroendocrine neoplasm (C)
5	14	FS	Labrador Retriever	23.3	Mass dorsal to right eye	2.4	N/a
6	12	FS	American Pit Bull Terrier	23.6	Cervical mass	8.5	N/a
7	11	MC	Labrador Retriever	41.8	Dysphagia, coughing, laryngeal paralysis	11.6	Neuroendocrine neoplasm (C)
8	9	MC	Boxer	22.8	Coughing, dysphonia, dysphagia	20	Neuroendocrine neoplasm (C)
9	6	MC	Labrador Retriever	43.5	Cervical mass	11	Malignant neoplasia with strong suspicion of mesenchymal neoplasm (C)
10	7	MC	Mixed breed	25.9	Cervical mass, cough, dysphonia, lethargy	7	N/a
11	12	MC	Labrador Retriever	32	Cough, lethargy	12	Thyroid carcinoma (B)
12	13	FS	Mixed breed	25.3	Cervical mass	Unknown	Mesenchymal neoplasm (C)
13	10	MC	Labrador Retriever	32	Cervical mass, cough, stertor	13.7	Mesenchymal neoplasm (C)
14	12	MC	Mixed breed	14.7	Cervical mass, PU/PD, polyphagia, weight loss	4.7	Neuroendocrine neoplasm (C)

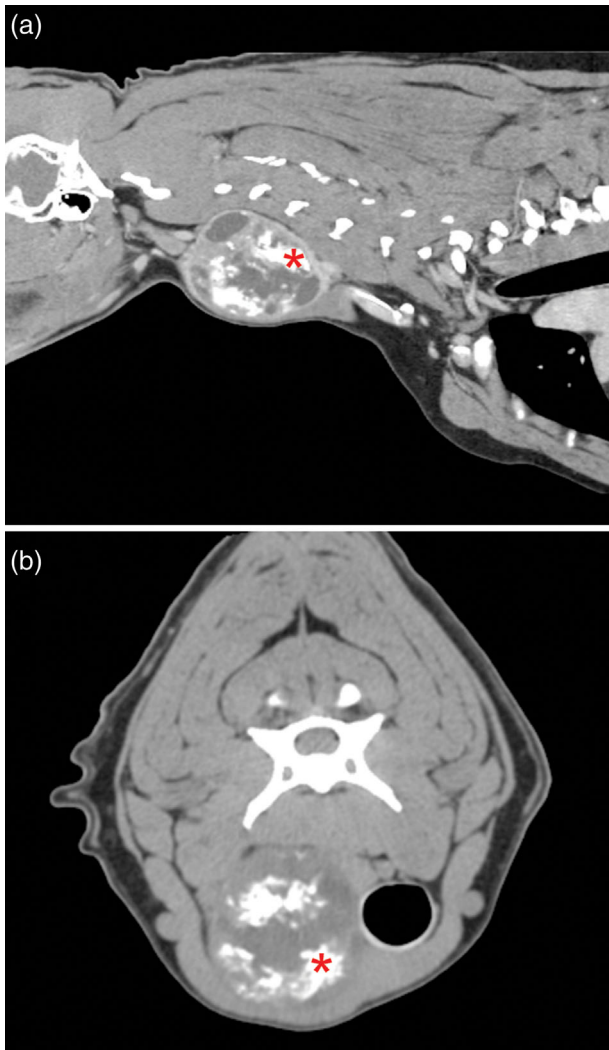
FS, female spayed; MC, male castrated.

consistent with pneumonia. One of the 12 dogs (dog 5) had a positron emission tomography-CT (PET-CT) scan using 3.46 mCi  $F^{18}$ -FDG radioisotope. This study showed multiple small pulmonary nodules (1–3 mm), which were suspected to be granulomas or pulmonary fibrosis rather than pulmonary metastatic disease based on a combination of density and margination. Abdominal ultrasound was performed in five dogs and no evidence of metastatic disease and no clinically relevant abnormalities were reported. Cervical CT scans were performed in 11/14 dogs. Thyroid masses were identified in all dogs. Based on CT measurements (7/13), physical exam (5/13), or measurement of the mass by pathology after removal (1/13), the median maximum tumour dimension was 9.0 cm (range 2.4–20.0 cm, IQR 5). Laterality of the thyroid mass was reported in 13 dogs and was left-sided in seven dogs and right-sided in six dogs. In one dog, laterality could not be determined due to the local extent and size of the mass. Mineralisation of the thyroid mass was observed in 6/11 dogs (Figure 1).

Fine needle aspirates and cytologic evaluation was performed in 9/14 dogs (Table 1). One dog (dog 1) had a cytopathologic diagnosis of a mixed neoplasm, with both neuroendocrine and mesenchymal neoplastic elements being present. Four of nine dogs had a cytologic diagnosis consistent with a neuroendocrine tumour or thyroid carcinoma,

whereas 2/9 dogs were diagnosed cytologically with a mesenchymal tumour. One dog (dog 3) had septic and mixed inflammation present without overt cytologic evidence of neoplasia. Incisional biopsies were performed in two dogs and the histopathologic diagnosis was consistent with a grade III soft tissue sarcoma (dog 2) and a thyroid carcinoma (dog 11).

All 14 dogs underwent curative-intent surgery to remove the thyroid neoplasm. The most common surgery performed was a unilateral thyroidectomy (10/14 dogs). In one dog (dog 6), a bilateral thyroidectomy was performed due to the presence of masses in both thyroid glands. In three dogs (dogs 11, 13 and 14), en bloc resection with thyroidectomy was performed due to local invasion of the primary tumour into adjacent tissues. Additional procedures were performed in four dogs due to the extent or involvement of surrounding structures. Dog 8 underwent removal of the left external parathyroid gland and left thyroarytenoid lateralisation. In dog 13, en bloc resection with laryngectomy to include both thyroids and parathyroids was performed. In dog 7, the left recurrent laryngeal nerve was noted to be extending into the tumour and was resected at the time of surgery. Finally, in dog 3, marginal resection of an oropharyngeal mass was performed. Surgical complications were seen in three dogs. Post-operative hypocalcaemia



**FIGURE 1** Post-contrast sagittal (a) and transverse (b) CT scan images of the cervical region from dog 10. Note the multifocal areas of mineralisation within the thyroid (red asterisk)

was seen in three dogs that resolved with time and medical management (dogs 6, 13 and 14). No additional surgical complications were reported.

Histopathologic samples were requested from all dogs and were collected and evaluated from 10/14 dogs. Outside institutions selected slides from one formalin-fixed, paraffin-embedded block of tissue for submission even though the thyroid masses had multiple tissue sections. Given the heterogeneity of the tumour architecture, the reviewing pathologist could not verify the presence of concurrent epithelial malignancy together with the malignant mesenchymal tissue in 4 of the 10 samples. In dog 14, the malignant epithelial component was surrounded by desmoplasia which multifocally formed osteoid; however, the mesenchymal cells did not demonstrate features of malignancy, and mitoses were not identified in the mesenchymal population. In dogs 1–3, sarcoma was definitively diagnosed, whereas evidence of epithelial malignancy could not be verified. Rare entrapped normal thyroid follicles stained with cytokeratin and TTF-1; however, the majority of the

tissue sections were composed of malignant mesenchymal cells (Figure 2). In these dogs, a review of the initial pathology report was performed to confirm that both components were present in other sections of the tumour. In dog 4, two slides were submitted and clearly showed carcinoma in one tissue section and sarcoma in the other.

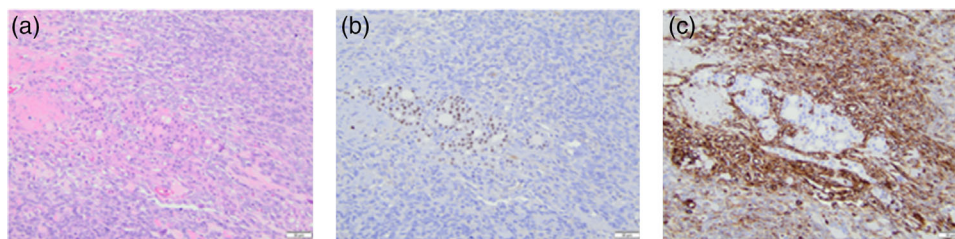
Regarding results of the immunohistochemical staining, the cells with an epithelial morphology stained with pan-cytokeratin as expected. Likewise, the mesenchymal cells demonstrated strong cytoplasmic labelling for vimentin. Staining for TTF-1 was more variable. For dogs 1–3 where neoplastic epithelial cells were minimal to absent, TTF-1 staining was negative or minimal, only staining the entrapped normal thyroid follicles. In dogs 4, 9, 11 and 14, TTF labelled the nuclei of neoplastic epithelial cells. Interestingly, in dog 12, approximately 20% of cells with a mesenchymal morphology demonstrated strong nuclear labelling for TTF-1 (Figure 3). Additionally, there was intravascular invasion by neoplastic cells which formed small nests with strong nuclear staining for TTF-1. This neoplastic tumour embolus was negative for both pan-cytokeratin and vimentin. In these dogs, a review of the initial pathology report was performed to confirm that both components were present in other sections of the tumour. Although an estimation of the percentage of neoplastic cell staining positive for the three IHC markers was attempted for all available samples, it was not possible in all samples, as some slides only had one type of tissue present in the submitted slide (i.e. dogs 1–3).

Histopathologic vascular invasion was identified in 4 of the 10 dogs (dogs 1, 2, 4 and 11). Tumour necrosis was present in all 10 dogs but comprised more than 50% of the reviewed slide in dogs 1, 4 and 11. The medial retropharyngeal lymph nodes were extirpated in four dogs (dogs 1, 4, 7 and 10). Metastatic disease was histopathologically identified within the retropharyngeal lymph nodes in 1/4 dogs (dog 7).

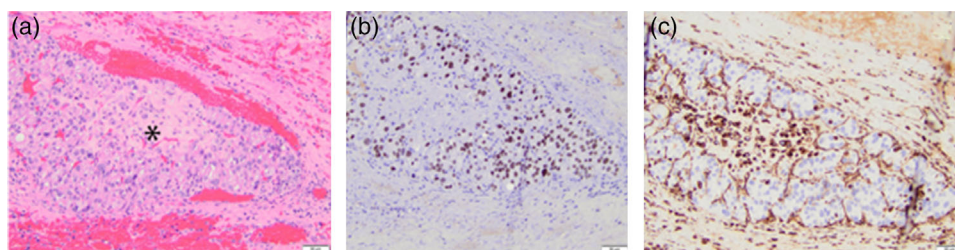
Postoperatively, systemic therapy was administered in 8/14 dogs. Six dogs received conventional maximum tolerated dose chemotherapy. Three dogs were given doxorubicin (25–30 mg/m<sup>2</sup> IV every 3 weeks; range 1–4 doses) and three dogs were given carboplatin (275–300 mg/m<sup>2</sup> IV every 3 weeks; range 1–6 doses). One dog was treated with adjuvant masitinib at 7.5 mg/kg PO every 24 hours. Two dogs were treated with adjuvant toceranib; one dog was treated with 2.3 mg/kg PO on Monday, Wednesday and Friday and the other dog was treated with 2.75 mg/kg PO on Monday, Wednesday and Friday after completion of carboplatin therapy.

Three dogs had metastatic disease identified at the time of initial presentation and seven dogs developed metastatic disease after surgical removal of their primary tumours. The most common metastatic site was the lungs (6/10 dogs). Three dogs developed metastatic disease to regional lymph nodes (medial retropharyngeal in two dogs and mandibular lymph node in one dog) and one dog (dog 3) developed metastatic disease to the spleen. The median TTM was 93 days (95% CI: 0–133, range 0–156 days) (Figure 4a). Six dogs developed presumptive locoregional recurrence of their mixed thyroid tumours. The median TTLR in dogs was 53 days (95% CI: 15–156, range 15–156 days).

Twelve of fourteen dogs died or were euthanised prior to data collection: 10 were euthanised due to progression or suspected progression of their mixed thyroid tumour either locally and/or systemically.



**FIGURE 2** Histology and immunohistochemistry from dog 1. The tissue section was almost entirely composed of spindlyoid mesenchymal cells with only a small focus of entrapped normal thyroid follicles (a). These follicles demonstrated strong nuclear labelling with TTF-1 (b). The surrounding neoplastic mesenchymal cells showed strong cytoplasmic labelling for vimentin, whereas the residual thyroid follicles were negative (c)



**FIGURE 3** Histology and immunohistochemistry from dog 12. There is a large tumour embolus (denoted by asterisk) within a vessel (a). The neoplastic cells that comprise the tumour embolus demonstrated strong nuclear labelling with TTF-1 (b). The stroma that encased the thyroid tumour embolus and the centre of the thrombus stained strongly for vimentin (c)

One dog was euthanised from progression of a previously diagnosed squamous cell carcinoma and one dog was euthanised after developing ascites. Two dogs were censored from survival analysis after being lost to follow-up 51 and 57 days after initial presentation. The median OST was 156 days (95% CI: 49–244) (Figure 4b). The median OST for dogs treated with adjuvant therapy was 189 days (95% CI: 24–244), whereas dogs without adjuvant therapy had a median OST of 156 days (95% CI: 35–upper limit could not be detected;  $p = 0.62$ ).

#### 4 | DISCUSSION

This study is the first to report on the outcome of a cohort of dogs with malignant mixed thyroid tumours with concurrent epithelial and mesenchymal components all treated with surgery. Similar to previous individual case reports, the OST for dogs with mixed thyroid tumours is short despite primary surgical excision with or without adjuvant systemic therapy. The results suggest that these tumours are a very aggressive malignancy in dogs. While also rare in humans, the outcomes described here are similar to outcomes in humans with thyroid carcinosarcomas where the survival is typically only a few months (al-Sobhi et al., 1997, Yang et al., 2018, Agrawal et al., 2013, Ekici et al., 2015). In one study of 17 reported humans with thyroid carcinosarcomas, the reported median survival time was 5 months (al-Sobhi et al., 1997).

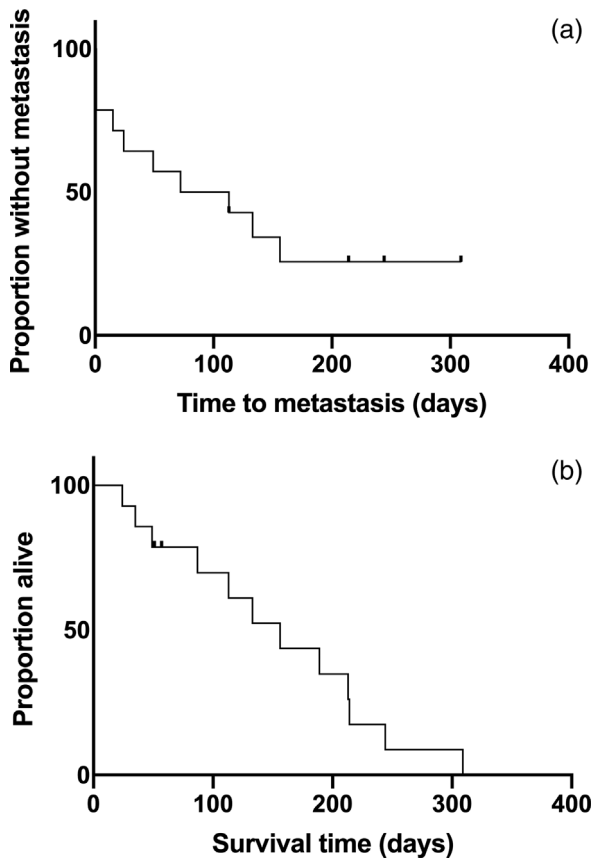
No statistically significant survival benefit was conferred with adjuvant systemic therapy in our study population. Although it may reflect a type-II error due to the small sample examined in this study, our results

suggest that thyroid tumours with epithelial and mesenchymal components are biologically aggressive and carry a poor prognosis even with surgery and adjuvant systemic therapy. Additional studies with larger numbers of patients and standardised staging and systemic therapy could further evaluate the potential benefit of systemic therapy in this patient population.

The pathogenesis of malignant mixed thyroid tumours is unknown. Presumably, these tumours originate from both mesenchymal and epithelial elements of the normal thyroid gland, as these malignancies collectively express TTF-1, cytokeratin and vimentin. While also rare in humans, one case report in which next-generation sequencing was performed on neoplastic cells revealed a point mutation in the *DICER1* gene (Yang et al., 2018).

The metastatic rate of thyroid carcinoma in dogs is high with 65–90% having metastatic disease at the time of death (Campos et al., 2014, Brodey & Kelly, 1968, Carver et al., 1995, Harari et al., 1986, Leav et al., 1976, Kent et al., 2002) with a reported TTM of 42 months (Campos et al., 2014). While dogs with mixed thyroid tumours in this study had a similar rate of metastatic disease (71.4%), the TTM was markedly shorter at approximately 3 months, suggesting a more aggressive biology for this neoplasm. Due to inconsistent re-staging and/or failure to confirm the presence of metastatic disease, it is possible that the rate of metastasis reported here was underestimated. Additionally, the reported metastatic rate may be an overestimate, as cytologic or histopathology confirmation of metastatic disease was not performed in all cases.

Although this study contained a small sample size, the percent of dogs with mineralised thyroid neoplasms was higher in dogs with mixed



**FIGURE 4** Kaplan–Meier curves for the time to metastasis (a) and overall survival time (b) for 14 dogs diagnosed with thyroid tumours with mesenchymal and epithelial components. The median time to metastasis was 93 days and the median overall survival time was 156 days. Censored patients are indicated by tick marks

thyroid tumours compared to thyroid carcinoma. Six of 11 dogs (55%) with advanced imaging of the neck (CT or PET-CT) were noted to have mineralisation of their primary mass. The reported rate of mineralisation observed in a previous study of dogs with thyroid carcinoma is 16% (Bertolini et al., 2017). As is also true of thyroid carcinomas in other studies, mixed thyroid tumours were typically large tumours with the median for the longest tumour dimension being 9 cm (Reagan et al., 2019). While rare, mixed thyroid tumours should be a differential diagnosis for a dog with a large, mineralised thyroid mass.

As a retrospective case series, limitations for this study include incomplete medical records, variable staging preoperatively and post-operatively and lack of standardised adjuvant treatment. Additionally, only 14 cases of mixed thyroid tumours were collected across nine sites, this likely speaks to the rarity of this neoplasm. Also, pathology review and IHC were only available for 10/14 dogs and histopathology reports were from various laboratories, making direct comparison and confirmation of their diagnosis impossible for those dogs. In the 10 dogs where pathologic samples were available for review, these tumours were noted to be very heterogeneous with varying amounts of epithelial and/or mesenchymal tissue. In four dogs, sections of tumour sent from other centres only contained one component of mixed thyroid tumour as multiple sections from the tumour were not

available for review. Although immunohistochemistry was helpful to identify cell lineages and invasive tumour emboli, we could not always verify staining patterns in neoplasms in which the epithelial and/or mesenchymal regions were sampled on other histopathology slides. In these dogs, a review of the initial pathology report was performed to confirm that both components were present in other sections of the tumour.

In conclusion, thyroid neoplasia with both epithelial and mesenchymal components appears to be an aggressive primary thyroid tumour seen in canines. Dogs with mixed thyroid tumours treated with surgery with or without adjuvant systemic therapy seem to have a poor prognosis with high rates of locoregional recurrence and metastasis.

#### DISCLOSURE

The authors declare no conflicts of interest related to this report.

#### ACKNOWLEDGEMENTS

Immunohistochemical stains were performed by the Comparative Pathology & Digital Imaging Shared Resource, Department of Veterinary Biosciences and the Comprehensive Cancer Center, The Ohio State University, Columbus, OH, and supported in part by grant P30 CA16058, National Cancer Institute, Bethesda, MD.

#### ETHICS STATEMENT

The authors confirm that the ethical policies of the journal, as noted on the journal's author guidelines page, have been adhered to. No ethical approval was required as this is a case series looking back at outcomes of clinical cases.

#### AUTHOR CONTRIBUTION

Matthew Cook: Conceptualisation, data curation, formal analysis, writing—original draft, writing—review & editing.

Molly Gasparini: Data curation, formal analysis, methodology, writing—original draft, writing—review & editing.

Rachel Cianciolo: Data curation, investigation, methodology, resources, writing—original draft, writing—review & editing.

Megan Brown: Conceptualisation, writing—review & editing.

Antony Moore: Resources, writing—review & editing.

Kaitlin Curran: Data curation, resources, writing—review & editing.

Elizabeth Maxwell: Data curation, resources, writing—review & editing.

Shelby Gasson: Data curation, writing—review & editing.

Brandan Wustefeld-Janssens: Data curation, resources, writing—review & editing.

Sridhar Veluvolu: Data curation, resources, writing—review & editing.

Samuel Keepman: Data curation, resources, writing—review & editing.

Raelene Wouda: Data curation, resources, writing—review & editing.

Lynn Griffin: Data curation, resources, writing—review & editing.

Laura Selmic: Conceptualisation, data curation, formal analysis, methodology, project administration, resources, supervision, writing—original draft, writing—review & editing.

## PEER REVIEW

The peer review history for this article is available at <https://publons.com/publon/10.1002/vms3.703>.

## DATA AVAILABILITY STATEMENT

The data that support the findings of this study are available from the corresponding author upon reasonable request.

## ORCID

Matthew R. Cook  <https://orcid.org/0000-0003-1825-2161>

Antony S. Moore  <https://orcid.org/0000-0002-8402-4100>

Kaitlin M. Curran  <https://orcid.org/0000-0003-4745-9727>

Elizabeth A. Maxwell  <https://orcid.org/0000-0002-8201-040X>

Laura E. Selmic  <https://orcid.org/0000-0001-6695-6273>

## REFERENCES

- Agrawal, M., Uppin, S. G., Challa, S., & Prayaga, A. K. (2013). Carcinosarcoma thyroid: An unusual morphology with a review of the literature. *South Asian Journal of Cancer*, 2(4), 226.
- al-Sobhi, S. S., Novosolov, F., Sabancı, U., Epstein, H. D., Greenspan, F. S., & Clark, O. H. (1997). Management of thyroid carcinosarcoma. *Surgery*, 122(3), 548–552.
- Barber, L. G. (2007). Thyroid tumors in dogs and cats. *Veterinary Clinics of North America. Small Animal Practice*, 37, 755–773.
- Benjamin, S. A., Lee, A. C., & Saunders, W. J. (1999). Classification and behavior of canine mammary epithelial neoplasms based on life-span observations in beagles. *Veterinary Pathology*, 36(5), 423–436.
- Bertolini, G., Drigo, M., Angeloni, L., & Caldin, M. (2017). Incidental and non-incident canine thyroid tumors assessed by multidetector row computed tomography: A single-centre cross sectional study in 4520 dogs. *Veterinary Radiology & Ultrasound: The Official Journal of the American College of Veterinary Radiology and the International Veterinary Radiology Association*, 58(3), 304–314.
- Brodey, R. S., & Kelly, D. F. (1968). Thyroid neoplasms in the dog. A clinicopathologic study of fifty-seven cases. *Cancer*, 22, 406–416.
- Buergelt, C. D. (1968). Mixed thyroid tumors in two dogs. *Journal of the American Veterinary Medical Association*, 152(11), 1658–1663.
- Campos, M., Ducatelle, R., Rutteman, G., Kooistra, H. S., Duchateau, L., de Rooster, H., Peremans, K., & Daminet, S. (2014). Clinical, pathologic, and immunohistochemical prognostic factors in dogs with thyroid carcinoma. *Journal of Veterinary Internal Medicine*, 28, 1805–1813.
- Canadas, A., França, M., Pereira, C., Vilaça, R., Vilhena, H., Tinoco, F., Silva, M. J., Ribeiro, J., Medeiros, R., Oliveira, P., Dias-Pereira, P., & Santos, M. (2019). Canine mammary tumors: Comparison of classification and grading methods in a survival study. *Veterinary Pathology*, 56(2), 208–219.
- Carver, J. R., Kapatkin, A., & Pataik, A. K. (1995). A comparison of medullary thyroid carcinoma and thyroid adenocarcinoma in dogs. A retrospective study of 38 cases. *Veterinary Surgery*, 24, 315–319.
- Ekici, M. F., Kocak, C., Bayhan, Z., Zeren, S., Yaylak, F., Metineren, M. H., & Kocak, F. E. (2015). Carcinosarcoma of the thyroid gland. *Case Reports in Surgery*, 2015, 494383.
- Fernandez, N. J., Clark, E. G., & Larson, V. S. (2008). What is your diagnosis? Ventral neck mass in a dog. *Veterinary Clinical Pathology*, 37(4), 447–451.
- Giuliano, A., Grant, J., & Benoit, J. (2013). Thyroid carcino-sarcoma in a dog. *Journal of the South African Veterinary Association*, 84(1), E1–E5.
- Grubor, B., & Haynes, J. S. (2005). Thyroid carcinosarcoma in a dog. *Veterinary Pathology*, 42(1), 84–87.
- Harari, J., Patterson, J. S., & Rosenthal, R. C. (1986). Clinical and pathologic features of thyroid tumors in 26 dogs. *Journal of the American Veterinary Medical Association*, 188, 1160–1164.
- Hirai, T., Mubarak, M., Kimura, T., Ochiai, K., & Itakura, C. (1997). Apocrine gland tumor of the eyelid in a dog. *Veterinary Pathology*, 34(3), 232–234.
- Johnson, J. A., & Patterson, J. M. (1981). Multifocal myxedema and mixed thyroid neoplasm in a dog. *Veterinary Pathology*, 18(1), 13–20.
- Kent, M. S., Griffey, S. M., Verstraete, F. J. M., Naydan, D., & Madewell, B. R. (2002). Computer-assisted image analysis of neovascularization in thyroid neoplasms from dogs. *American Journal of Veterinary Research*, 63, 363–369.
- Leav, I., Al, S., Rijnberk, A., Legg, M. A., & der Kinderen, P. J. (1976). Adenomas and carcinomas of the canine and feline thyroid. *American Journal of Pathology*, 83, 61–122.
- Lieske, D. E., & Rissi, D. R. (2020). A retrospective study of salivary gland diseases in 179 dogs (2010–2018). *Journal of Veterinary Diagnostic Investigation*, 32(4), 604–610.
- Mason, R., & Wells, H. G. (1929). On the occurrence of true mixed carcinomatous and sarcomatous tumors (sarcomatoma) with report of mixed carcinoma-chondrosarcoma of the thyroid of a dog. *American Journal of Cancer (Journal of Cancer Research)*, 13, 207–210.
- Moisan, P. G., Watson, G. L. (1996). Ceruminous gland tumors in dogs and cats: A review of 124 cases. *Journal of the American Animal Hospital Association*, 32(5), 448–452.
- Pérez-Martínez, C., García Fernández, R. A., Reyes Avila, L. E., Pérez-Pérez, V., González, N., & García-Iglesias, M. J. (2000). Malignant fibrous histiocytoma (giant cell type) associated with a malignant mixed tumor in the salivary gland of a dog. *Veterinary Pathology*, 37(4), 350–353.
- Rasotto, R., Berlatto, D., Goldschmidt, M. H., & Zappulli, V. (2017). Prognostic significance of canine mammary tumor histologic subtypes: nn observational cohort study of 229 Cases. *Veterinary Pathology*, 54(4), 571–578.
- Reagan, J. K., Selmic, L. E., Fallon, C., Sutton, B., Lafferty, M., Ben-Aderet, D., Culp, W. T. N., Liptak, J. M., Duffy, D., Simons, M., Boston, S., & Lana, S. (2019). Complications and outcomes associated with unilateral thyroidectomy in dogs with naturally occurring thyroid tumors: 156 cases (2003–2015). *Journal of the American Veterinary Medical Association*, 255(8), 926–932.
- Salas, G., Román, O., Gutiérrez Díaz-Ceballos, M. E., & Constantino, F. (2002). Lung carcinosarcoma in a dog: gross and microscopic examination. *Veterinary Journal*, 163(3), 331–334.
- von Sandersleben, J., & Hänichen, T. (1974). Tumours of the thyroid gland. *Bulletin of the World Health Organization*, 50(1–2), 35–42.
- Wells, H. G. (1901). Multiple primary malignant tumors: report of a primary sarco-carcinoma in the thyroid of a dog, with mixed sarcomatous and carcinomatous metastases. *Journal of Pathology and Bacteriology*, 7, 357–367.
- Yang, J., Sarita-Reyes, C., Kindelberger, D., & Zhao, Q. (2018). A rare malignant thyroid carcinosarcoma with aggressive behavior and DICER1 gene mutation: A case report with literature review. *Thyroid Research*, 11, 11. Published 2018 Jul 31.

**How to cite this article:** Cook, M. R., Gasparini, M., Cianciolo, R. E., Brown, M. E., Moore, A. S., Curran, K. M., Maxwell, E. A., Gasson, S., Wustefeld-Janssens, B. G., Veluvolu, S. M., Keepman, S., Wouda, R., Griffin, L. R., & Selmic, L. E. (2022). Clinical outcomes of thyroid tumours with concurrent epithelial and mesenchymal components in 14 dogs (2006–2020). *Veterinary Medicine and Science*, 8, 509–516. <https://doi.org/10.1002/vms3.703>